

# Oral cancer rehabilitation: Requirement and responsibility of maxillofacial prosthodontist's (MFP's)

Jinesh A Dugad<sup>1\*</sup>, Smita Athavale<sup>2</sup>, Gunjan Chouksey<sup>1</sup> and Ravish Tongya<sup>3</sup>

<sup>1</sup>Prosthodontist and Implantologist, Ex Research fellow TMH Parel, Consultant SA-AIO Hospital, Mumbai, India

<sup>2</sup>Consultant Maxillofacial Prosthodontist, Deenanath Mangeashkar hospital & research centre, Pune, India

<sup>3</sup>Prosthodontist and Implantologist, Senior lecturer, Index institute of dental sciences, Indore, India

## Abstract

**Objective:** A patient with oral cancer receives prosthesis, which can help them achieve optimum esthetic, function and form through total oral rehabilitation. Maxillofacial Prosthodontists (MFPs) play an important role in the management of head and neck cancer patients from the preliminary stage of treatment planning. However, their role is often less understood. The objective of the article is to provide a brief insight into the requirement and role of MFP's in management of patients with head and neck cancer.

**Discussion:** There is not a more severely handicapped person than a patient with gross facial disfigurement. Since the most exposed portion of his body is unkindly distorted, he / she often undergoes callous indignities and social trauma because of this abnormality.

**Implication for practice:** Taking into account, the prevalence of functional and cosmetic deficits, there is a need for patient-centric approach for addressing every aspect of their problems.

## Introduction

Oral cancer is one of the major health problems. 2.5 lakhs new patients are diagnosed in India alone of whom about three-fourths are in an advanced stage [1]. Worldwide, it is considered to be the fifth most common cancer with the seventh highest cancer mortality [2].

Oral cancer care has ceased to be merely cure-oriented treatment, such as ablative surgeries, radiotherapy, chemotherapy etc. which results in various residual deformities and dysfunction. Taking into account, the prevalence of functional and cosmetic deficits, there is a need for patient-centric approach for addressing every aspect of their problems. Therefore 'Rehabilitation' is an essential phase of cancer care.

Today, hospitals are becoming the centers for comprehensive health care. Complete rehabilitation of head & neck cancer (HNC) patients is achieved using a multidisciplinary team approach. It involves several specialties like Onco-Surgeons, General surgeons, Plastic surgeons, Physicians, Medical oncologist, Radiotherapist, Physiotherapist, Maxillofacial Prosthodontist (MFP), Speech therapist, Nutritionist, Occupational therapist, Psychologist, Rehabilitation nurse, Social worker, Recreational therapist [3]. It is recognized that patients may have different rehabilitation needs throughout their care pathway. Therefore, rehabilitation should be considered from the time of diagnosis in a complete & comprehensive treatment plan & not towards the end of it.

## Patients prospectus & fear

Patients are generally referred to dental professionals later for many reasons like teeth replacement, sharp teeth filing, dental/jaw related pain management, etc. Many a time's patients with oral cancer are unaware of the advances in prosthetics therapy eg. the possibility of fabricating an artificial palate (obturator) which would eliminate the requirement

of the feeding tube completely or use of guiding flange prosthesis at the earliest to retain and achieve functional alignment of remaining mandible and prevent jaw deviation (Figures 1a, 1b and 1c) [4]. Need and training of jaw separating/stretching exercises at a very early stage in patients suffering from trismus secondary to oncotherapy. This is essential to prevent difficulty in providing dental care & maintaining personal oral hygiene and future possible rehabilitation.

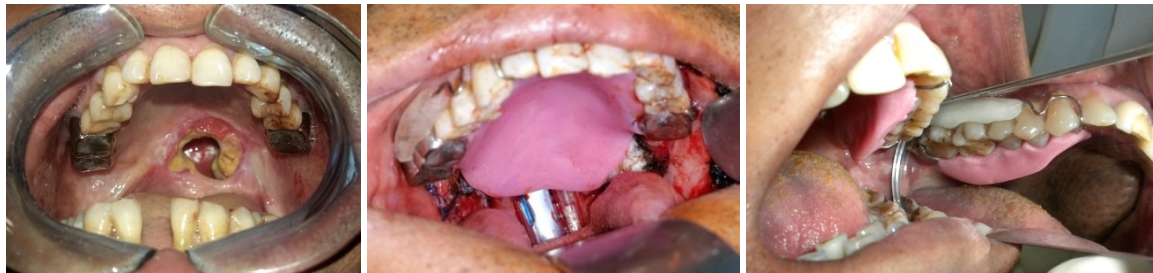Patients with total glossectomy are always in fear of inability to speak swallow, therefore these functional needs can be reasonably achieved with tongue prosthesis or palatal augmentation prosthesis (Figures 2a, 2b and 2c).

Apprehensive patients are most difficult to rehabilitate. These patients come for dental consultation with lot of predetermined expectations. It is therefore important to counsel them right from the first appointment and help them to face the facts in a very supportive way. Frequent follow-up visits and counselling is the key to build healthy relation between HNC patients and MFP's to achieve optimum rehabilitation. Otherwise, it becomes very difficult to educate them about the existing reality in their mouth and managing it effectively. Hence, with compassionate and practical approach, MFP's can build a positive relationship with HNC patients that will definitely improve quality of life of the patient.

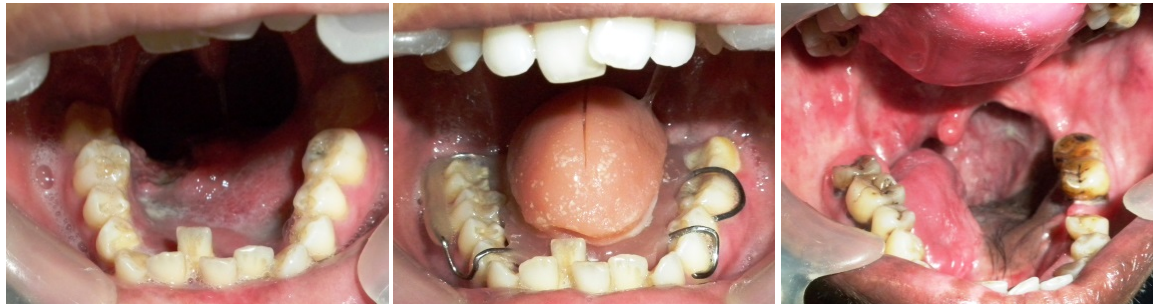
**Correspondence to:** Jinesh A Dugad, Prosthodontist and Implantologist, Ex Research fellow TMH Parel, Consultant SA-AIO Hospital, Mumbai, India, Tel. +91 9967771443; E-mail: jineshdugad@gmail.com

**Key words:** oral cancer, prosthesis, rehabilitation, prosthodontist

**Received:** August 20, 2017; **Accepted:** September 14, 2017; **Published:** September 17, 2017



**Figure 1.** (a) Intraoral defect (b) Obturator in place (c) Mandibular guiding plane prosthesis



**Figure 2.** (a) Intra oral defect (b) Tongue prosthesis in place (c) Palatal Augmentation prosthesis

### Role & responsibility of MFP's

Maxillofacial Prosthetics is the branch of Prosthodontics concerned with the restoration and / or replacement of the stomatognathic and craniofacial structures with prosthesis that may or may not be removed on a regular or elective basis [5]. In other words, it is rehabilitation by artificial substitute to body part lost due to cancer surgery, trauma etc and ensure reentering of the patients in the mainstream society.

Responsibility of MFP in managing HNC patients is twofold. Initial responsibility is to identify those complaints that are originating from dental perioral and masticatory sources so that it can be managed in dental operatory with dental methods and techniques. Secondly plan the rehabilitation keeping in mind prognosis of the prosthetic therapy.

They fulfill broad range of services in hospital setup such as intraoral and extra oral prosthesis, reconstructive plastic surgery, cleft palate team, temporomandibular disorder, dental implant therapy, management of patients receiving anti-resorptive therapy, anti-angiogenic drug therapy. It also involves the oral prophylaxis of all cancer patients in whom adequate oral hygiene and its maintenance is of utmost importance prior to cancer treatment for example surgery, chemotherapy, radiotherapy, bone marrow transplant etc. They advise necessary radiographic investigations of the jaws to figure out several existing dental and bone related issues that could be treated beforehand so that unwanted complications can be avoided later [6]. Pre-prosthetic surgery is very well planned and can be carryout to remove anatomic interferences and achieve healthy oral hard and soft tissue to receive future prosthesis [7]. The strategy and techniques of prosthetic phase depends on the site of involvement, its extent and type of surgical intervention, and use of modalities such as radiation and /or chemotherapy [8]. Designing and fabrication of intraoral or extra-oral prosthesis solely depends on the preservation of sound anatomical oral tissues, including teeth. Many a time's surgical enhancement is required to improve the existing anatomic configuration. This can be utilized to retain the prosthesis into the surgical defects. Hence surgeons can be informed about such surgical modifications if any beforehand for the betterment of prosthesis outcomes [9].

Upon MFP's rests a great responsibility; they must be able to differentiate between the degree of deformity present and complexity of treatment required to re-establish impaired function and improve the patients quality of life (QOL) [10]. They should make clear the total treatment to these patients, so that early knowledge of the rehabilitation phase will definitely prove beneficial psychologically.

The MFP's should assure the patients that extensive prosthodontic help will be provided to him after surgical treatment only [11]. They should be positive, confident and competent enough in personality and reasonable and co-operative in attitude to work effectively in a multidisciplinary environment. Schaaf NG states that MFP's is an important aspect of patient care in recent decades and in addition advancements in materials science and design has resulted in a whole array of possible prostheses that can be constructed to meet specific patient needs [12].

### Why to refer patients to MFP

MFP's is a key element in identifying the two striking problems, one with general health and other oral health related issues of HNC patients that he/she often comes across in their clinic.

The use of artificial substitute for replacement of orofacial defect has long been an accepted method of treatment. Although improvements in surgical techniques have often eliminated the need for artificial replacements, still there is a need for treating patients with acquired orofacial defects due to trauma, infectious disease, neoplastic disease etc [11].

Preoperative dental treatment is beneficial. Most of the preoperative dental procedures can be carried out within 24 hours of initial referral, this will help to avoid acute dental infection and related pain and also potential tissue and teeth support for prosthesis will not be jeopardized. The diseased/malposed/impacted teeth can be brought to the surgeons notice beforehand that can be removed regardless of the extent of surgical defect during the operation itself. Similarly, acute oral infections such as necrotizing ulcerative gingivitis will likely be exacerbated in a postoperative period when routine oral hygiene procedures are not easily practiced [12].

Craniofacial defects and extra-oral prosthesis such as orbital, ocular, conformer, auricular, nasal, cranial plates, combined intraoral and extra-oral defects etc. has a tremendous psychological, physical and functional impact on the quality of life of HNC patients [13].

Role of MFP's is less realized particularly in the HNC patients. Along with other experts these patients should be initially educated and informed about several effects of cancer treatments on dental rehabilitation and simultaneously with the help of referral to other specialties the patient can get optimum care. Therefore, absence of MFP from the treatment team would be detrimental to patient care and the ability of the patient/family to cope with the effects of the disease or its treatment on their functional capacity and QOL.

### When to refer

There is a continuing debate on preference or involvement of MFP for rehabilitation of patients who have undergone resection of head and neck tumors. The choice lies into the hands of the surgeons primarily to approach the restorative dentists to contribute their skills in reconstruction and rehabilitation of HNC patients. There are several studies that explored patient's opinion and attitude towards their prosthesis [14], studies about surgeon's preference to reconstruct or obturate [15]; study about Maxillofacial technician's perception about various aspects of maxillofacial prosthesis etc [16]. But the opinion and attitude of the Oncosurgeons towards MFP's in today's scenario is unknown.

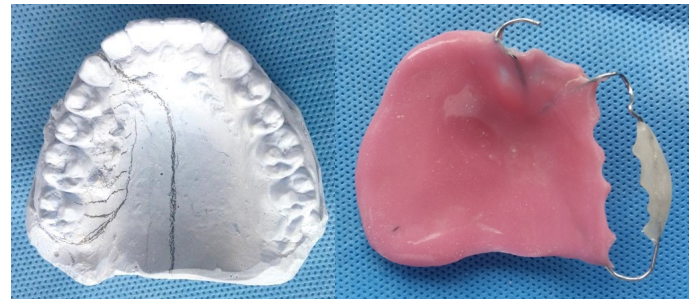HNC patients are concerned with the extent of their disease, the treatments received for total elimination of cancer, and its ultimate prognosis. The involved disease eradication process are often life-threatening that may make cure worse than the disease. Therefore, rehabilitation should be considered prior to creation of physiologic and cosmetic deficiencies [11]. During post-operative period patients are relatively uncomfortable due to facial incisions, swelling, coating of dried mucosa and blood on mucosa. They cannot maintain their oral hygiene adequately, thus making it impossible to obtain an accurate impression of the remaining structure. In order to, accomplish such procedures effectively, the Prosthodontist must be present at the initial treatment planning and make preoperative dental impressions.

Prosthesis planning always begins before undertaking any HNC surgeries and also in the interim phase between the time of surgical removal of a carcinoma and initiation of reconstructive plastic surgery (Figures 3a and 3b). Use of dental implants is increasingly implemented today in the prosthetic rehabilitation of these patients. There are literature showing that patients treated with implant-retained prosthesis resulted in the most favorable functional outcomes (Figures 4a and 4b) [12,17,18]. Patients referred after oncotherapy often enters the door of MFP's with high expectation while patients who were referred during treatment planning are mentally prepared about the reality, therefore treatment planning and dental therapy for these patients can be achieved satisfactorily.

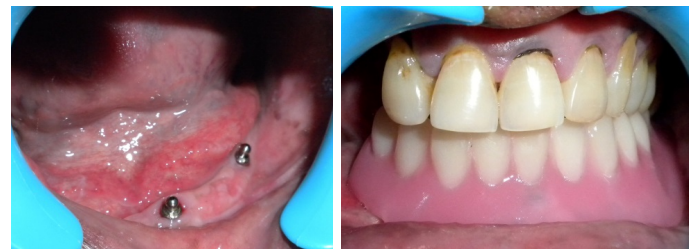### Scope

Maxillofacial prosthodontics as a profession has far improved with the advent of improving material science, osseointegrated implant therapy, CAD-CAM technology and rapid prototyping technics. The scope of these technological innovations lies in virtual designing and precise, lifelike fabrication of prosthesis hence revolutionized the outcome of prosthodontic rehabilitation [19,20].

MFP's proves to have an essential contribution in assessing the possibility of recurrence during long-term follow-up visits [21]. So



**Figure 3.** (a) Treatment planning on diagnostic cast (b) Preoperative surgical obturator



**Figure 4.** (a) Implant placement in residual mandible (b) Retentive functional denture in mouth

also, educating the patients with appropriate oral hygiene methods to preserve the optimum oral health and prevent future problems.

### Summary

Survival rate has significantly improved with the advent of advances in the management of oral malignancy [22]. Oral cancer rehabilitation goes beyond prosthetic reconstruction of orofacial defects to include complementing specialties providing holistic care. MFP's should be an integral part of a team of consultants in diagnosis, treatment planning and treating jaw irregularities and deformities. Their role and responsibility is definitely expandable and therefore its relationship to the hospital, patients and medical professionals has changed for the betterment.

Evolving trends and skills have helped the patients to overcome need for additional surgery. The results achieved from the prosthesis are often esthetically pleasing, functionally acceptable & from the patients perspective it is less traumatic than plastic surgery. Although normal function cannot be achieved but attempt to accomplish optimum functional outcomes by prosthesis is definitely helpful for the patients to maintain a normal life.

### References

- Desai C (2008) Squamous cell carcinoma of the head and neck region: insights from the American Society of Clinical Oncology 2008 presentations. *Indian J Cancer* 45: 90-92. [Crossref]
- Ferlay J, Shin HR, Bray F, Forman D, Mathers C, et al. (2010) Estimates of worldwide burden of cancer in 2008: GLOBOCAN 2008. *Int J Cancer* 127: 2893-2917. [Crossref]
- Bast RC Jr, Kufe DW, Pollock RE, Weichselbaum RR, Holland JF, Frei E III (2000) Principles of cancer rehabilitation medicine. In: *Holland-Frei Cancer Medicine*. 5th ed. Hamilton, Ontario: BC Decker Inc; 971-985.
- Beumer J, Esposito SJ, Marunick MT (2011) Maxillofacial rehabilitation: prosthodontic and surgical management of cancer-related, acquired, and congenital defects of the head and neck. 3rd Edi. Quintessence; 118-120.
- Markt JC, Lemon JC (2001) Extraoral maxillofacial prosthetic rehabilitation at the M. D. Anderson Cancer Center: A survey of patient attitudes and opinions. *J Prosthet Dent* 85: 608-613. [Crossref]
- Ali A, Fardy MJ, Patton DW (1995) Maxillectomy--to reconstruct or obturate? Results of a UK survey of oral and maxillofacial surgeons. *Br J Oral Maxillofac Surg* 33: 207-210. [Crossref]

7. Hatamleh MM, Haylock C, Watson J, Watts DC (2010) Maxillofacial prosthetic rehabilitation in the UK: a survey of maxillofacial prosthetists and technologists' attitudes and opinions. *Int J Oral Maxillofac Surg* 39: 1186-1189. [[Crossref](#)]
8. Schaaf NG (1984) Maxillofacial prosthetics and the head and neck cancer patient. *Cancer* 54: 2682-2690. [[Crossref](#)]
9. Schoen PJ, Raghoebar GM, van Oort RP, Reintsema H, van der Laan BF, et al. (2001) Treatment outcome of bone-anchored craniofacial prostheses after tumor surgery. *Cancer* 92: 3045-3050. [[Crossref](#)]
10. Fueki K, Kimoto K, Ogawa T, Garrett NR (2007) Effect of implant-supported or retained dentures on masticatory performance: a systematic review. *J Prosthet Dent* 98: 470-477. [[Crossref](#)]
11. Kim DD, Ghali GE (2011) Dental implants in oral cancer reconstruction. *Oral Maxillofac Surg Clin North Am* 23: 337-345. [[Crossref](#)]
12. [No authors listed] (2005) The glossary of prosthodontic terms. *J Prosthet Dent* 94: 10-92. [[Crossref](#)]
13. Vissink A, Burlage FR, Spijkervet FK, Jansma J, Coppes RP (2003) Prevention and treatment of the consequences of head and neck radiotherapy. *Crit Rev Oral Biol Med* 14: 213-225. [[Crossref](#)]
14. Bruins HH1, Koole R, Jolly DE (1998) Pretherapy dental decisions in patients with head and neck cancer. A proposed model for dental decision support. *Oral Surg Oral Med Oral Pathol Oral Radiol Endod* 86: 256-267. [[Crossref](#)]
15. Zlotolow I (2001) Dental oncology and maxillofacial prosthetics. *Cancer of the Head and Neck* 1: 376.
16. Beumer J, Zlotolow I, Curtis TA (1990) Réhabilitation. In: Silverman S, editor. *Oral Cancer*. 3rd ed. Atlanta: American Cancer Society; 127-148.
17. Tang JA, Rieger JM, Wolfaardt JF (2008) A review of functional outcomes related to prosthetic treatment after maxillary and mandibular reconstruction in patients with head and neck cancer. *Int J Prosthodont* 21: 337-354. [[Crossref](#)]
18. Desjardins RP (1977) Early rehabilitative management of the maxillectomy patient. *J Prosthet Dent* 38: 311-318. [[Crossref](#)]
19. Sykes LM, Parrott AM, Owen CP, Snaddon DR (2004) Applications of rapid prototyping technology in maxillofacial prosthetics. *Int J Prosthodont* 17: 454-459. [[Crossref](#)]
20. Bailey BJ, Johnson JT, Newlands SD (2000) Surgical techniques to enhance prosthetic rehabilitation. In: *Head and Neck Surgery- Otolaryngology*. 4th ed. Philadelphia: Lippincott Williams and Wilkins; 1864.
21. Khan Z, Farman AG (2006) The Prosthodontic's role in head and neck cancer and introduction- Oncologic dentistry. *J Indian Prosthodont Soc* 6: 4-9.
22. Shaw RJ, Sutton AF, Cawood JI, Howell RA, Lowe D, et al. (2005) Oral rehabilitation after treatment for head and neck malignancy. *Head Neck* 27: 459-470. [[Crossref](#)]