

The purple urine bag syndrome

Pauline Vanderweckene¹, Christiane Counasse² and Jean-Marie H Krzesinski^{1*}

¹Department of Nephrology, University of Liège, Belgium

²Revalidation unit CHU Liège, University of Liège, Belgium

Case

An 81-year-old man was hospitalized for a long time in geriatric unit for a meningeal hemorrhage with secondary hydrocephalus. He underwent a ventriculoperitoneal shunt but had limited mobility with confusion and needed chronic urinary tract catheter. He has mainly cardiovascular history (coronary bypass, ventricular arrhythmia, hypertension, atrial fibrillation and pace make). During hospitalization, his chronic kidney disease has increased (eGFR 30 mL/min) and he has presented constipation requiring laxative medication. One day, the health care team noticed the purple coloration of the urine bag (Figure 1). A urinalysis showed pyuria, and an alkaline pH (pH 8). The urine culture yielded *E. Coli* and *K. Pneumoniae* (growth was greater than 10⁶ CFU/mL for both). The purple urine bag syndrome was diagnosed.

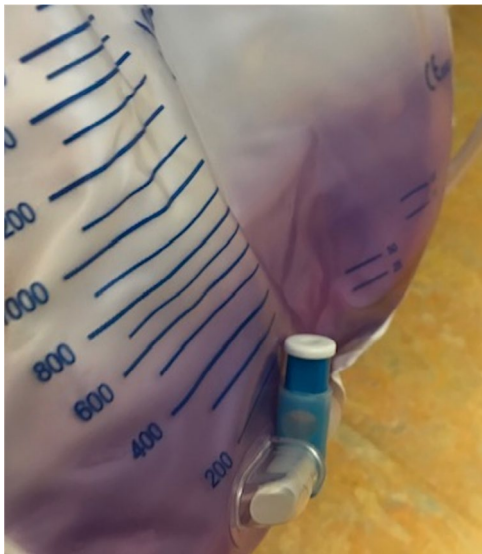


Figure 1. Purple color of the urine in the plastic bag collector

Discussion

This syndrome is sometimes observed in cases of urinary infection in bed-ridden patients with long-term indwelling urinary catheters, constipation and alkaline urinary pH [1].

It was first described in 1978 and the mechanism only understood in 1988 [2].

The purple urine bag syndrome is linked to intestinal bacterial overgrowth, secondary to constipation, with an increase of dietary tryptophan metabolism into indol products absorbed and conjugated to indoxyl sulfate metabolites in the liver, then excreted in the urine with a transformation into indoxyl by sulfatases and phosphatases produced by urinary bacteria, these include *Escherichia Coli*, *Proteus Mirabilis*, *Morganella morganii*, *Klebsiella pneumoniae*, *Providencia stuartii*, *Providencia rettgeri* et *Pseudomonas Aeruginosa*. The indoxyl products are then converted into indigo (blue) and indirubin (red) metabolites, the mixture of which causes the purple color in the plastic urine bag.

The prognosis is usually good, depending on proper management of infection [3].

References

1. Su K (2005) Case analysis of purple urine-bag syndrome at a long-term care service in a community hospital. *Chang Gung Med J* 28: 636-642.
2. Dealer SF (1988) Enzymatic degradation of urinary indoxyl sulfate by *Providencia stuartii* and *Klebsiella pneumoniae* causes the purple urine bag syndrome. *J Clin Microbiol* 26: 2152-2156.
3. Su, Wang (2019) Risk factors of mortality in patients with purple urine bag syndrome. *Journal of Drug Assessment* 8: 21-24.

Copyright: ©2020 Vanderweckene P. This is an open-access article distributed under the terms of the Creative Commons Attribution License, which permits unrestricted use, distribution, and reproduction in any medium, provided the original author and source are credited.

***Correspondence to:** Jean-Marie Krzesinski, Department of Nephrology, CHU Liège B35 4000 Liege, Belgium, E-mail: jm.krzesinski@chuliege.be

Received: January 27, 2020; **Accepted:** February 20, 2020; **Published:** February 24, 2020